STANDARDIZED PATIENTS AND SONOGRAPHY IN A BASIC MEDICAL ANATOMY COURSE

Valerie L. Fulmer, BA; John B. Schumann PhD; Ryan A. Murray, BS; Hollis D. Day, MD; and John F. Mahoney, MD

University of Pittsburgh School of Medicine

Introduction

Standardized Patients (SPs) regularly participate in medical school activities and, typically, portray a patient with a specific background and complaint (case). However, SPs can also participate in events where his or her body is utilized for imaging purposes, such as basic sonography instruction to reinforce applied anatomy concepts.

During the first-year medical student (MS-1) Medical Anatomy course, which includes didactic sessions and open dissections, faculty noticed the students' desire to see a living body system in order to apply knowledge to real-life situations.

This curricular intervention was implemented to determine if the addition of ultrasound on SPs would augment the students' knowledge of anatomy acquired through traditional teaching methods (e.g., didactic components and dissection) and also improve the students' understanding of the clinical relevance of anatomical principles.

The ultrasound lectures and demonstrations occurred toward the end of the Medical Anatomy course (during the extremities section of the course) so that the students would be able to compare real–time sonographic imaging on an SP with recently completed cadaver dissections and prosections in the lab.

Methods

During two initial didactic sessions, clinical faculty described basic ultra sound, physics, knobology, and ultrasound terminology. Additionally, a clinical member of the Department of Anesthesiology introduced a specific application—to guide peripheral nerve blocks for post operative pain relief. The instructor encouraged the students to review these areas in their cadaver dissections both before and after the ultrasound demonstrations.

Two SPs were employed for the laboratory sessions. Each SP was previously scanned to exclude pathology and ensure they were comfortable with the scanning process.

Two dissection groups consisting of twelve students were assigned to thirty-minute scanning sessions facilitated by one of two clinician instructors. The groups rotated every thirty minutes, allowing the entire class of students to participate.

The students were first given a basic overview of the sonogram machine and the linear probe and were given information regarding frequencies and image resolution. The ultrasound appearance of arteries, veins, muscle, bone, fascia, and nerves were described.

While not required, the students were encouraged to actively participate in the scanning. Students were again encouraged to compare their dissections with the ultrasound images they viewed on the SPs.

Results

When asked in course evaluations more than 50% of student evaluations from 2010-2013 rated the ultrasound event as beneficial to the selected areas of anatomy studied.

In 2013 the class evaluation was modified to represent the entire class rather than a sample. The actual 2013 evaluations are included here and are considered more accurate statistically.

As the graph shows, 58% of the students strongly agreed or agreed that the standardized patient ultrasound session was helpful to learning and understanding.

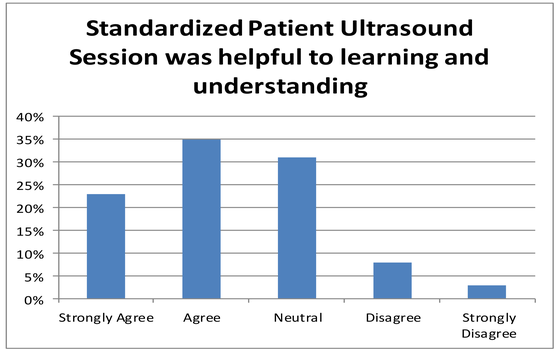

Student comments from overall course evaluations were very positive and included statements such as:

"*Relating ultrasound images to concepts currently learning in anatomy allowed us to see the difference between classroom/real life, where not everything is perfect*."

"*The ultrasound experience came at a great time….and it allowed us to see the immediate and practical use of what we've been studying. And it was amazing to visualize these structures in a new way and in living subjects. I liked that it was very hands on.* "

Conclusions

This real-time and dynamic evaluation with ultrasonography appeals to our new generation of technologically savvy students. Introducing ultrasound on SPs to reinforce anatomy is time consuming and resource intensive, but appears to be a very effective addition to traditional methods of teaching gross anatomy.

Future Directions

We are discussing areas of improvement. Student comments such as *"… I found myself rather lost as the faculty member stated how clearly some veins or arteries were appearing, whereas I saw just gray and black blobs "* indicate that improvements can be made. We are also considering the expansion of ultrasound exposure in the course and the possibility of testing student knowledge of anatomical structures using ultrasound. This year we will add the basics of cardiac ultrasound, demonstrating on the SP some of the important views that one can obtain and normal echo anatomy.

References

Angtuaco, T. L., Hopkins, R. H., DuBose, T. J., Bursac, Z., Angtuaco, M. J., & Ferris, E. J. (2007). Sonographic physical diagnosis 101: Teaching senior medical students basic ultrasound scanning skills using a compact ultrasound system. *Ultrasound quarterly*, *23*(2), 157-160.

Brown, B., Adhikari, S., Marx, J., Lander, L., & Todd, G. L. (2012). Introduction of ultrasound into gross anatomy curriculum: Perceptions of medical students. *The Journal of emergency medicine*, *43*(6), 1098-1102.

Dreher, S. M., DePhilip, R., & Bahner, D. (2013). Ultrasound Exposure During Gross Anatomy. *The Journal of emergency medicine*, *46*(2), 231-240.

Jurjus, R. A., Dimorier, K., Brown, K., Slaby, F., Shokoohi, H., Boniface, K., & Teresa Liu, Y. (2013). Can anatomists teach living anatomy using ultrasound as a teaching tool?. *Anatomical sciences education*. Advance online publication. doi: 10.1002/ase.1417

Wittich, C. M., Montgomery, S. C., Neben, M. A., Palmer, B. A., Callahan, M. J., Seward, J. B., & Bruce, C. (2002). Teaching cardiovascular anatomy to medical students by using a handheld ultrasound device. *Jama*, *288*(9),1062-1063.

Ziv, Stephen D. Small, Paul Root Wolpe, A. (2000). Patient safety and simulation-based medical education. *Medical teacher*, *22*(5), 489-495.

For additional information contact: vfulmer@medschool.pitt.edu 412-648-8702